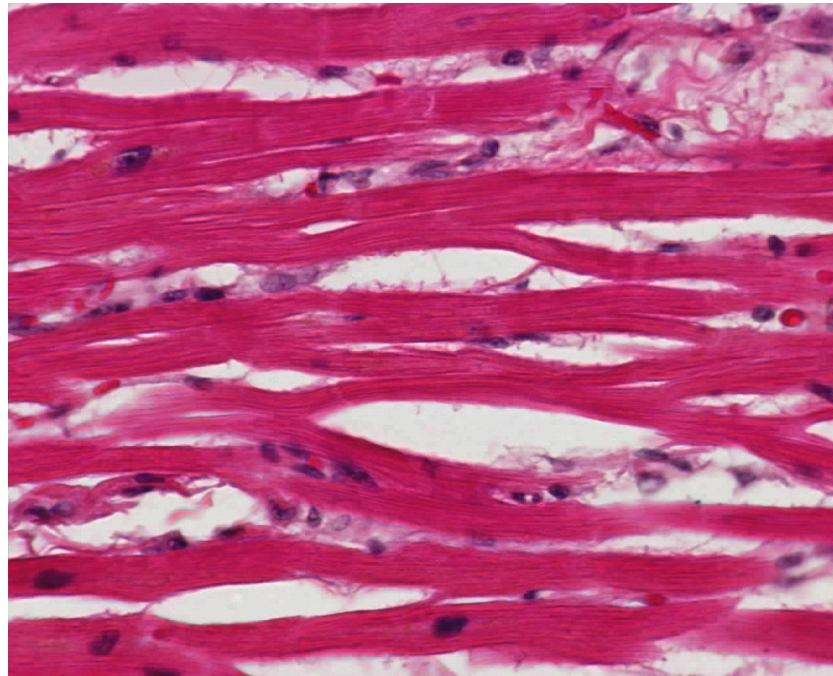
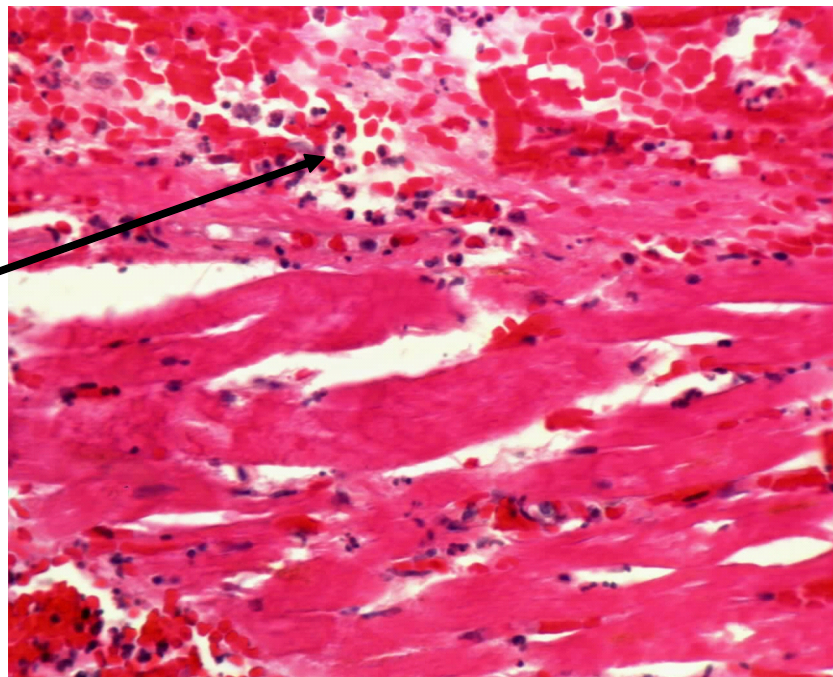


Histology Report

Myocardial Reference Slides



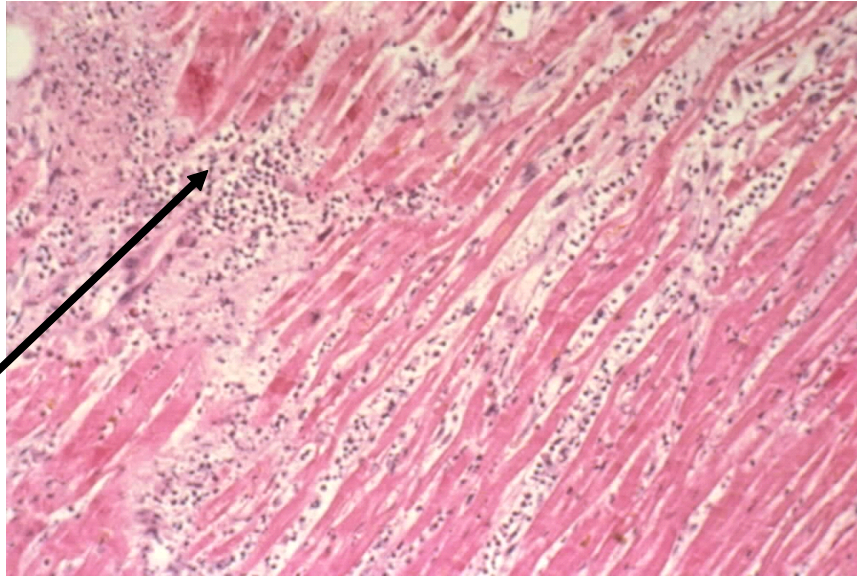
Normal Heart Tissue



Increased number of black dots indicates inflammation.

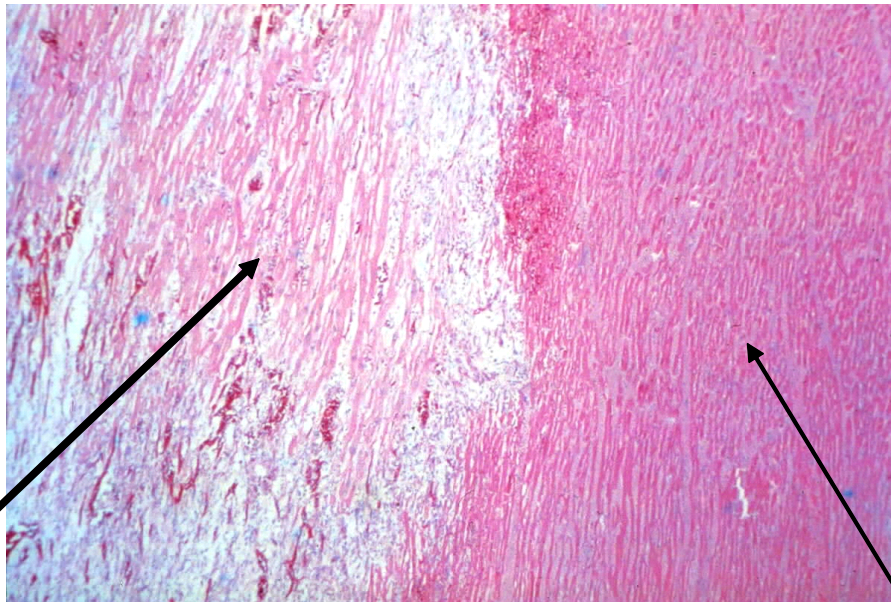
8 – 12 Hours After Myocardial Infarction (MI)

Myocardial Reference Slides



Increased number of black dots indicates inflammation.

2 – 4 Days After MI Shows Loss of Muscle Tissue

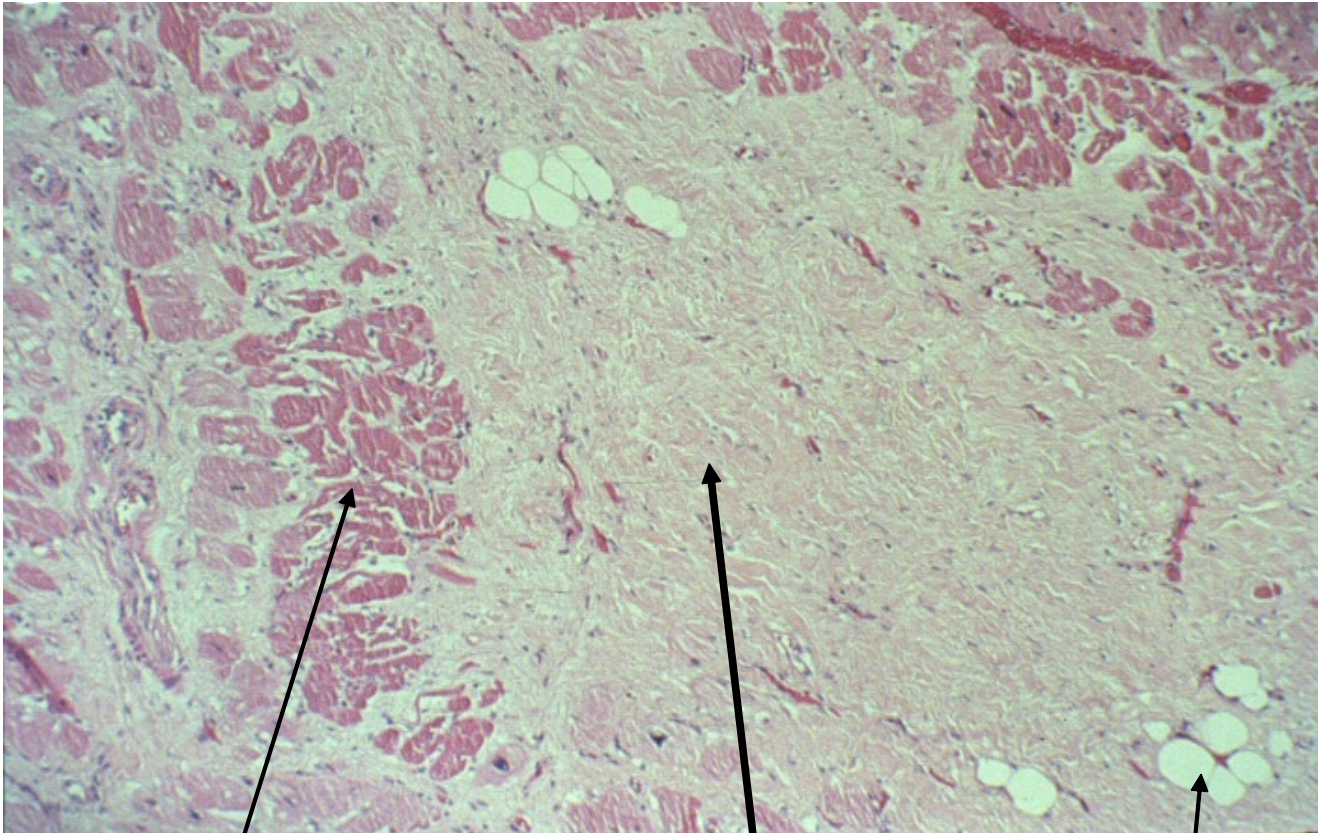


White tissue indicates healing - granulation of tissue.

Healing MI

Healthy tissue with good blood supply

Myocardial tissue slide from Case Number: 55269M

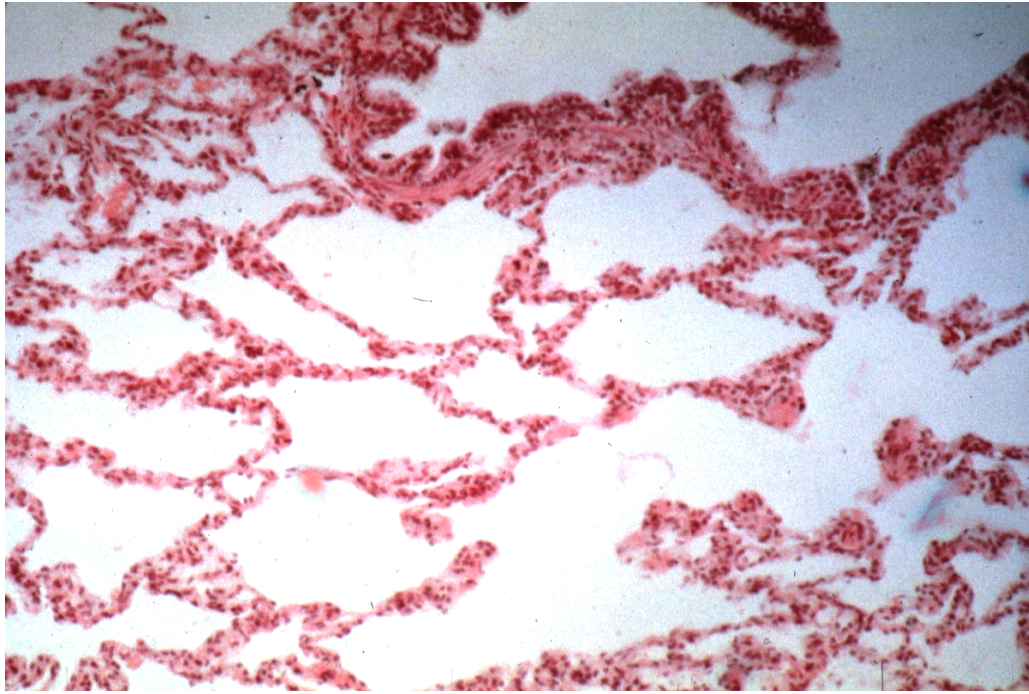


**Some healthy
tissue with
good blood
supply**

White tissue indicates scarring.

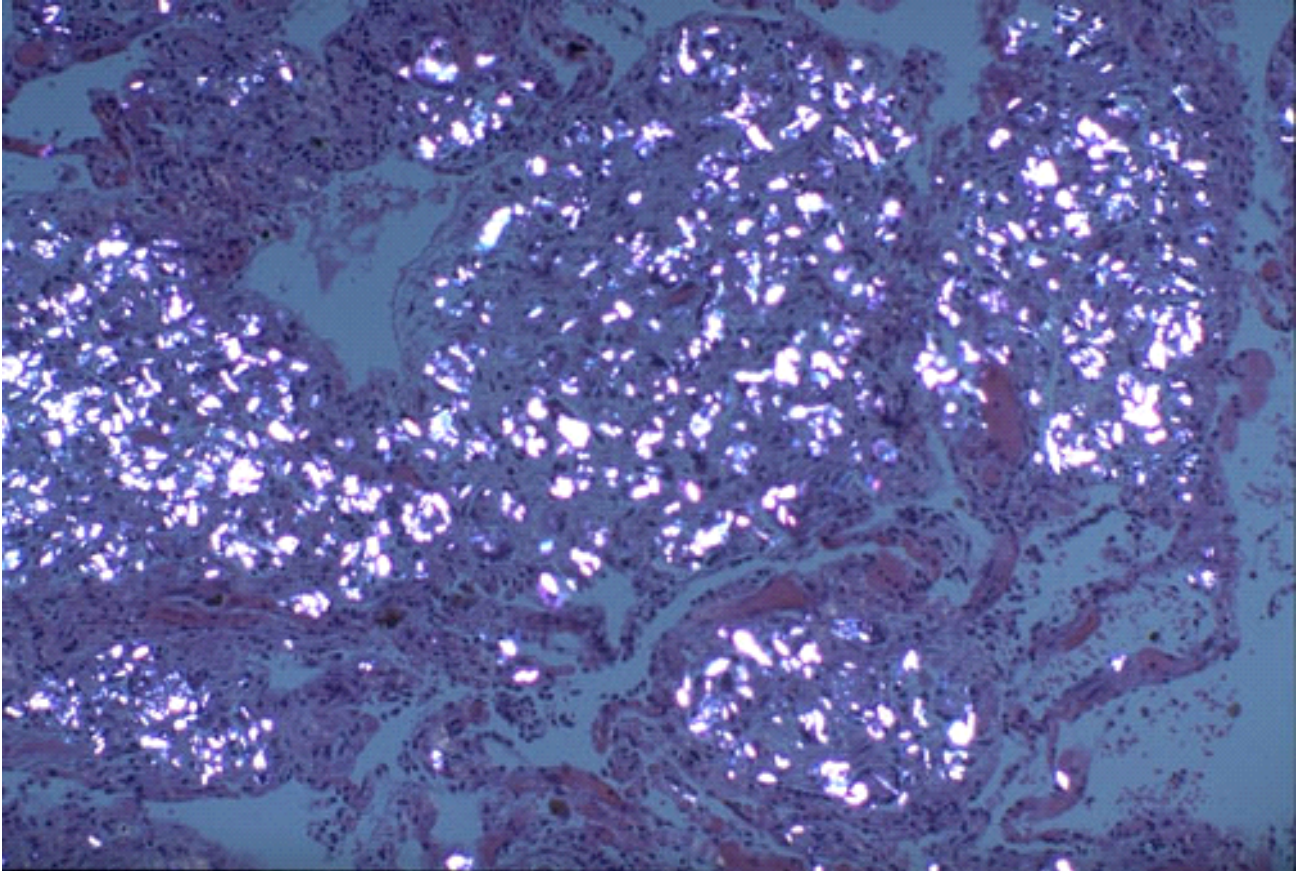
Fat vacuoles

Lung Tissue Reference Slide



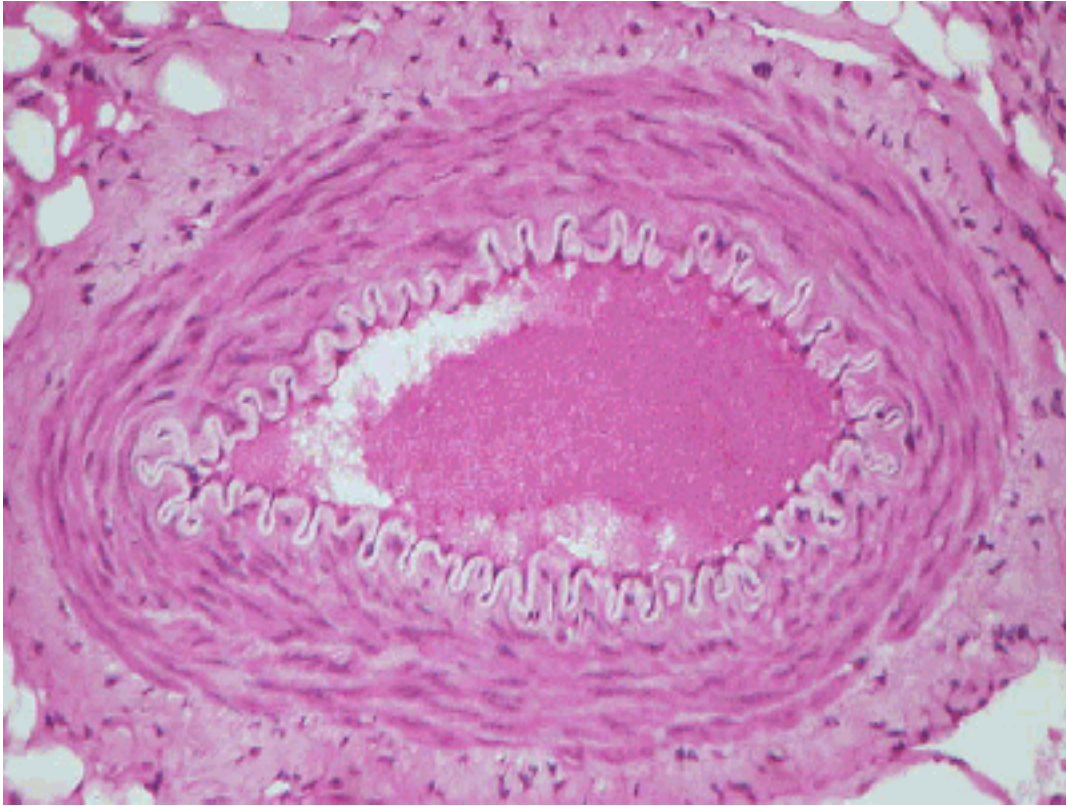
Normal Lung Tissue

Lung tissue from Case Number: 55269M



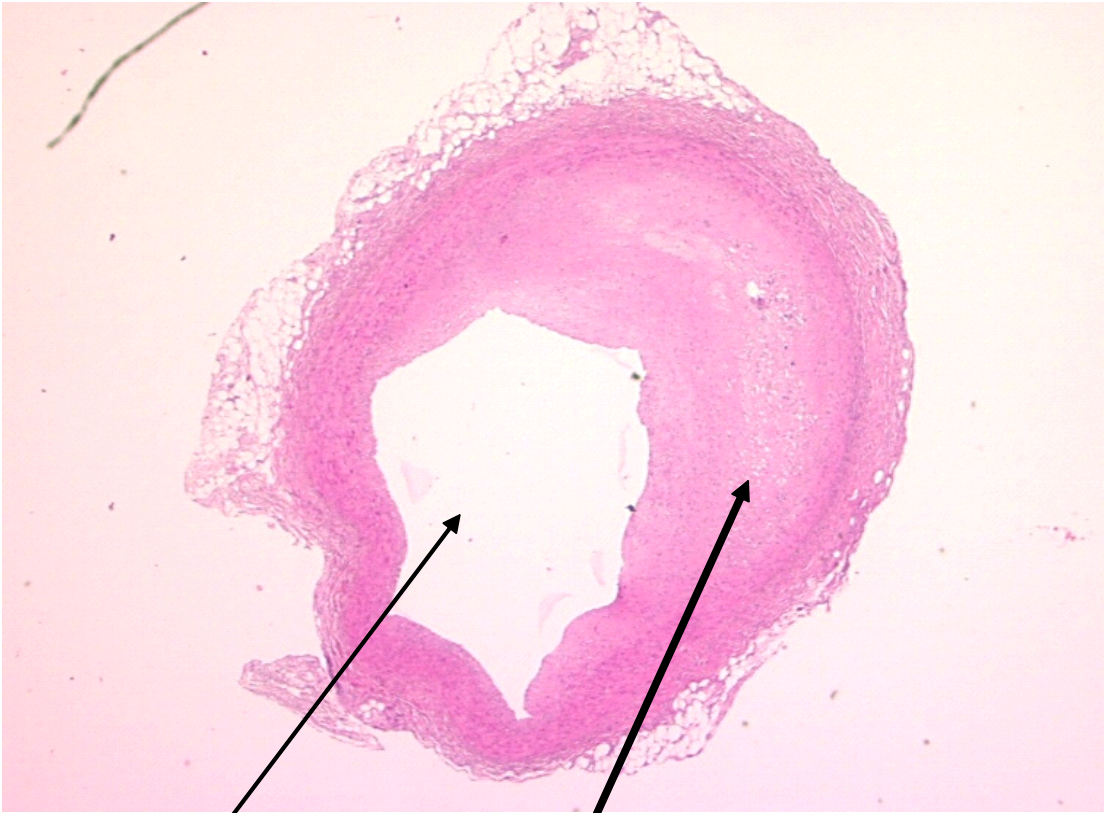
White spots indicate talc granules found in the lungs. Talcum powder is a soft metal and is often mixed with illicit drugs Talc is not soluble and will remain in the lungs indefinitely.

Coronary Artery Reference Slide



**Normal Coronary Artery
with blood in the center and
the artery wall surrounding
it.**

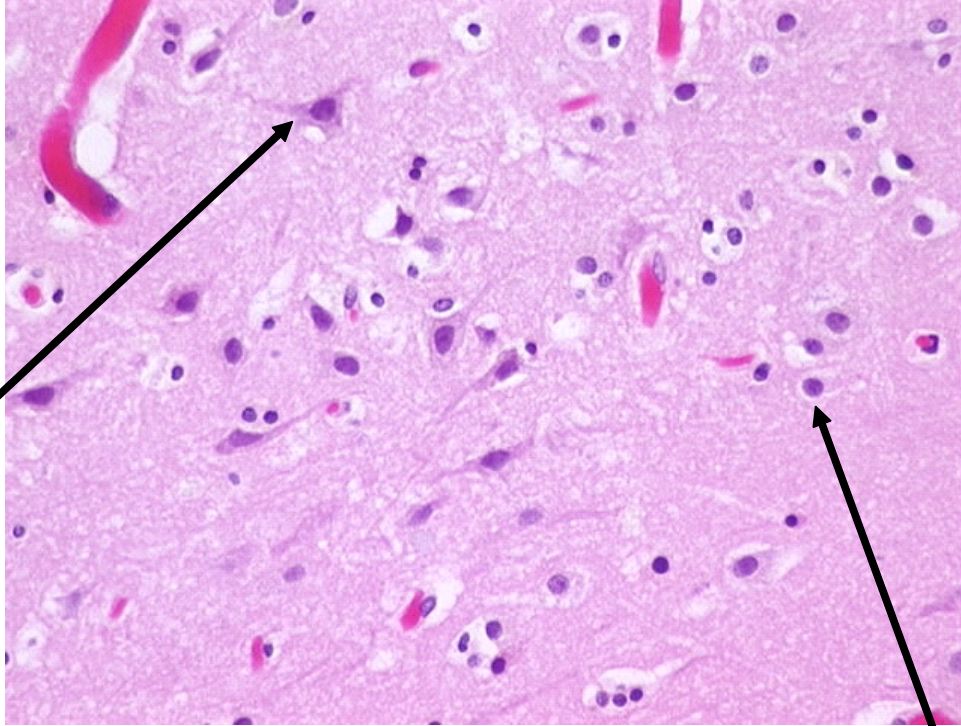
Coronary artery tissue from Case Number: 55269M



**Open area for
blood to flow**

Blockage

Brain Tissue Reference Slide

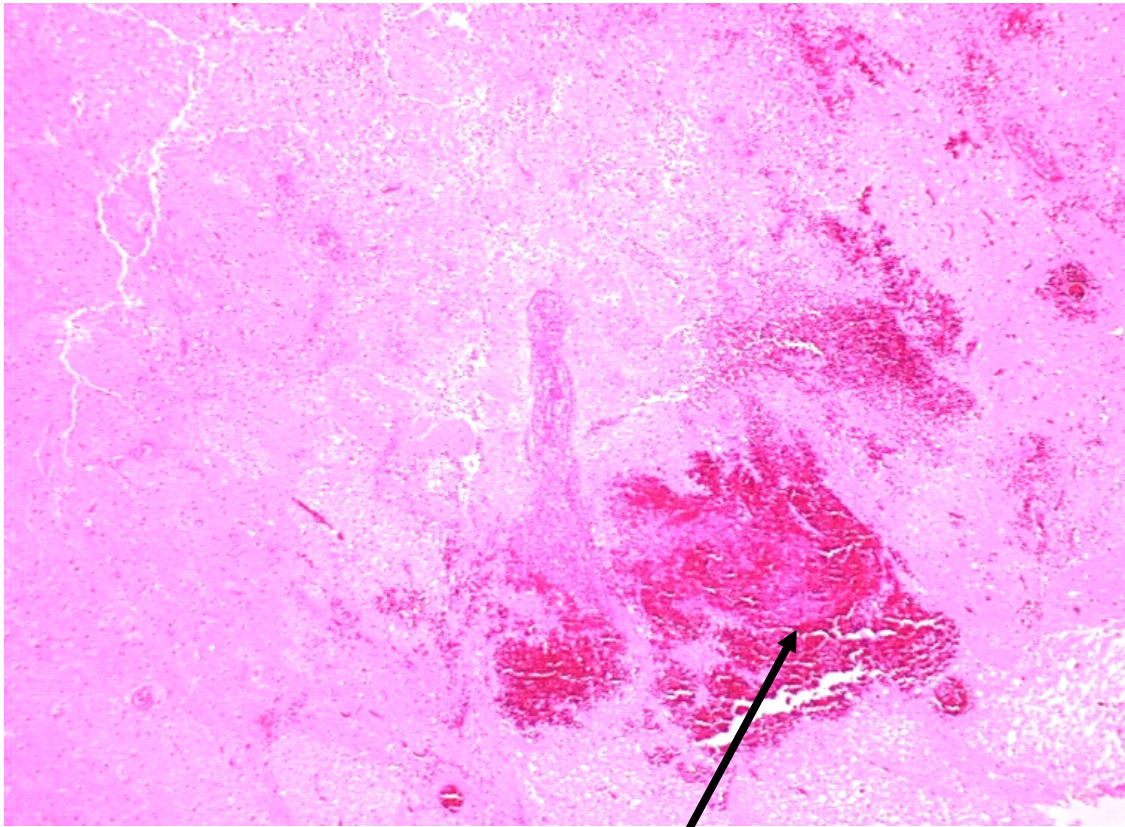


The dark purple, almost triangular areas are neurons.

Normal Brain Tissue

The purple circles are glial tissue

Brain tissue from Case Number: 55269M



Hemorrhage